



## Abdominal Cocoon: A Rare and Difficult Togetherness in Trauma Patient

### Abdominal Koza: Travmalı Hastada Nadir ve Zor Bir Birliktelik

Abdominal Cocoon Syndrome

Erkan Oymacı<sup>1</sup>, Erdem Barış Cartı<sup>2</sup>, Ahmet Deniz Uçar<sup>2</sup>, Ali Coşkun<sup>2</sup>, Mehmet Yıldırım<sup>2</sup>, Nazif Erkan<sup>2</sup>  
<sup>1</sup>Gastroenterological Surgery Department, <sup>2</sup>General Surgery Department,  
Izmir Bozyaka Training and Research Hospital, Izmir, Turkey

Bu çalışma Mayıs 2012 İzmir, 18. Ulusal Cerrahi Kongresinde poster bildirimi olarak sunulmuştur.

#### Özet

Sklerozan enkapsüle peritonit olarak bilinen abdominal koza, ince barsakların fibrokollejenöz bir membran ile tamamen yada kısmen sarıldığı nadir bir mekanik intestinal obstrüksiyon nedenidir. Genç adolesan kadınlarda görülmekte ve olguların büyük bir kısmında etyoloji bilinmemektedir. Cerrahi acil vakalarda bu nadir olgunun akılda tutulması tedavide gecikmeleri önleyebilir ve hasta için gereksiz girişimleri engelleyebilir. Travma nedeni ile opere ettiğimiz ve teşhis ve tedavide zorlanmaya neden olan abdominal koza olgusunu sunuyoruz.

#### Anahtar Kelimeler

Peritonit; Multipl Travma; Genel Cerrahi

#### Abstract

Abdominal cocoon, as known sclerosing encapsulating peritonitis, is a rare condition of mechanical intestinal obstruction due to total or partial encapsulation of the small bowel by a fibrocollagenous membrane. It has been reported mainly in young adolescent women and the majority of the cases are of unknown etiology. Awareness of this rare cause of surgical emergency may prevent delay in treatment and avoid unnecessary procedures for the patient. We are presenting an operated abdominal cocoon case which can be cause difficulty in diagnose and treatment.

#### Keywords

Peritonitis; Multiple Trauma; General Surgery

DOI: 10.4328/JCAM.1492

Received: 24.12.2012 Accepted: 27.02.2013 Printed: 01.07.2016

J Clin Anal Med 2016;7(4): 545-7

Corresponding Author: Erkan Oymacı, Gastroenterological Surgery Department, Izmir Bozyaka Training and Research Hospital, Izmir, Turkey.

T.: +905052692741 F.: +90 2322505050 E-Mail: erkan.oymaci@hotmail.com

Introduction

Abdominal cocoon, or sclerosing encapsulating peritonitis, is a rare cause of small-bowel obstruction that results from encasement of variable lengths of bowel by a thick fibrotic capsule. It was first described by Foo et al in 1978 [1]. The etiology of this condition

is not well understood; however, it is a form of chronic irritation and inflammation. It can be classified as either idiopathic or secondary . The idiopathic form primarily affects young women from tropical countries [2]. The secondary form has been associated with long-term peritoneal dialysis , ventriculoperitoneal shunts , long-term  $\beta$ -blocker therapy, abdominal tuberculosis , abdominal surgery , liver transplantation , sarcoidosis, systemic lupus erythematosus, gastrointestinal malignancy, and protein S deficiency [3, 4, 5].

In most patients preoperative diagnosis is difficult and is usually diagnosed at laparotomy. We report an abdominal cocoon case who was together with intestinal perforation caused by trauma in surgical emergency unit.

Case Report

A 32 -year-old male patient was admitted to our emergency surgical department with complaint of abdominal pain due to traffic accident. In the physical examination, there were signs of peritoneal irritation all quadrants of the abdomen with rebound tenderness. Blood pressure was 100/60 mmHg and heart rate was 120 /minute. A slightly distention was observed at abdominal examination and the bowel sounds were decreased. Also lung sound was decreased at the left side with auscultation. Blood tests showed elevated levels of C-reactive protein and WBC count and decreased heamoglobin level. Abdominal USG and computerized tomography revealed that spleen injury, heamo-pneumothorax at the left thoracic cavity and distention of the distal jejunum and proximal ileum segment with a large amount of fluid collection around the spleen. The patient underwent an emergency laparotomy with a diagnosis of acute abdomen after left tube thoracostomy . There were intraabdominal hemorrhagic fluid and grade 3 spleen injury during the operational evaluation. The bowels were found to be encapsulated in a thick membrane which is causing obstruction 40 cm beyond the Trietz ligament. The major omentum was missing. We also saw intestinal fluid content from the fibrotic wall of encapsulated bowel segment [Figure1]. The patient underwent bridectomy, and the adhesions were freed by careful dissections in order to prevent iatrogenic bowel injuries. The membrane, which surrounded all the small-bowel loops from the Treitz ligament to the ileocecal valve and perforated intestinal segment was resected [Figure 2]. Intestinal anastomosis was performed. The postoperative course was uncomplicated. The patient was further questioned regarding secondary causes of abdominal cocoon syndrome. There was no positive history of these causes. The patient was allowed to feed via oral intake by the 5th post-operative day, and stool discharge occurred on the 7th post-operative day. The patient was discharged on the 8th postoperative day. The histopathologic analysis of the specimen was reported as fibrosis, mononuclear infiltrative inflammation and filiform view of mucosa [Figure 3]. The serosal surface showed a proliferation of fibro-connective tissue, inflammatory infiltrates,

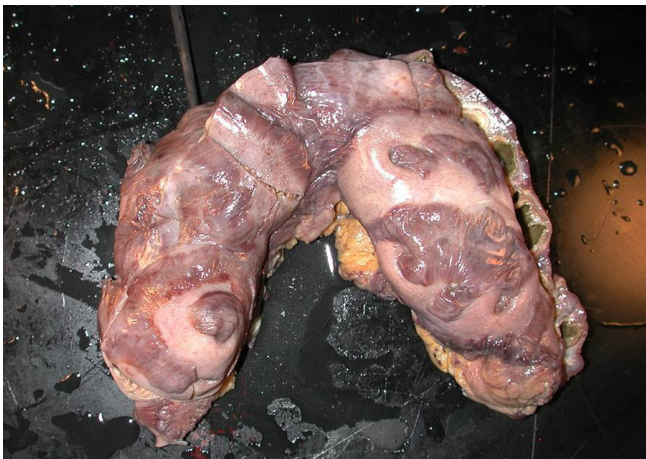

Figure 1. The fibrotic wall of encapsulated bowel segment

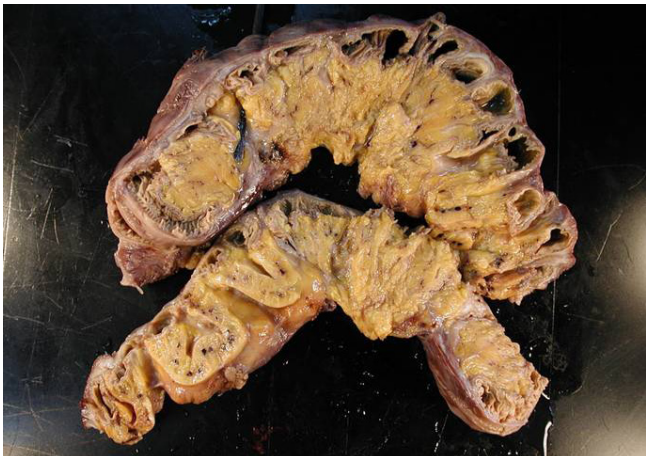

Figure 2. Fibrotic wall of perforated intestinal segment which resected

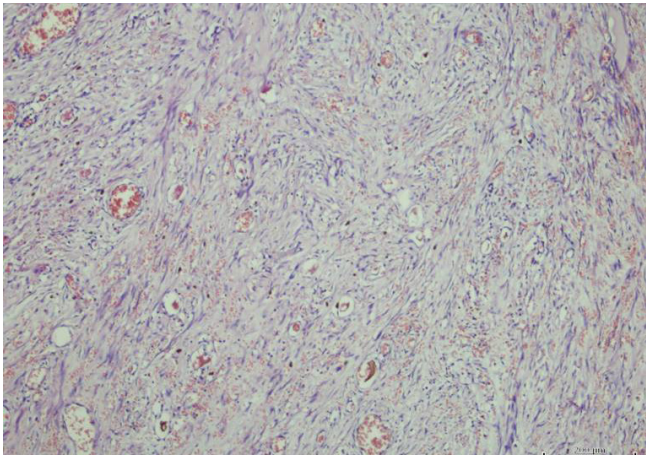


Figure 3. Fibrosis, mononuclear infiltrative inflammation and filiform view of mucosa

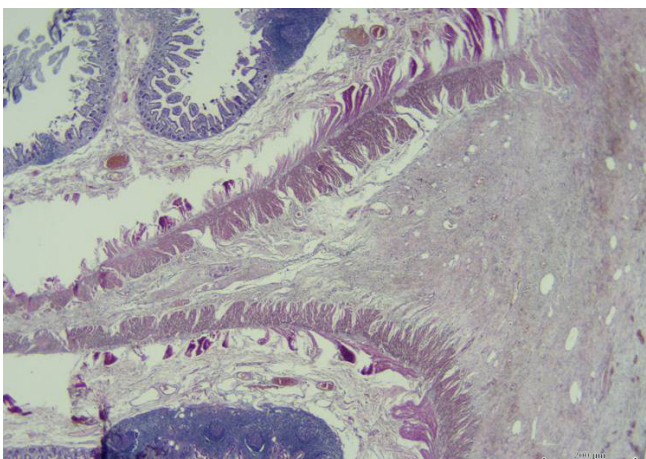


Figure 4. A proliferation of fibro-connective tissue, inflammatory infiltrates, and vascular proliferation

and vascular proliferation [Figure 4].

The patient is healthy and no symptoms of bowel obstruction on follow-up.

## Discussion

Abdominal cocoon, the idiopathic form of sclerosing encapsulating peritonitis, is a rare condition of unknown etiology that results in an intestinal obstruction due to total or partial encapsulation of the small bowel by a fibrocollagenous membrane. It was first observed by Owtschinnikow in 1907 and was called peritonitis chronica fibrosa incapsulata [9]. Abdominal cocoon was first described by Foo et al [1]. It is an acquired condition that is often idiopathic. Geographically, it tends to be confined to the tropical and subtropical regions. It is generally found exclusively in females, although about 10 cases in adult males have been reported in the literature [6,7,8]. To explain the etiology, a number of hypotheses have been proposed. These include retrograde menstruation with a superimposed viral infection, retrograde peritonitis and cell-mediated immunological tissue damage incited by gynecological infection. The pathogenesis of abdominal cocoon syndrome remains unknown; however, the etiopathogenesis correlates to congenital dysplasia, chronic symptomatic peritonitis, some medicines (e.g., practolol), continuous ambulatory peritoneal dialysis, and district and sexuality factors [10,11]. The absence of the major omentum in our case may suggest the association of some unknown genetic factors that play a role in the pathogenesis of idiopathic disease [12]. The clinical presentation of the abdominal cocoon syndrome mostly occurs as acute abdomen, which, in most cases, requires surgical intervention. Preoperative diagnosis of the syndrome is usually difficult [13]. Various treatment options are adopted, such as subtotal excision of the membrane, enterolysis, small bowel intubation, bowel resection, and exploratory laparotomy with postoperative medical treatment in patients with high perforative risk [14]. Laparotomy reveals characteristic gross thickening of the peritoneum, which encloses some or all of the small intestine in a cocoon of opaque tissue. Fibrous bands form between the loops of bowel, and when the mass of bowel is sectioned, many small loculated abscesses due to local perforations are found. Careful dissection and excision of the thick sac with the release of the small intestine leads to complete recovery.

In order to avoid complications of postoperative intestinal leakage and short-intestine syndrome, resection of the bowel is indicated only if it is nonviable or perforated because resection of the bowel increases morbidity and mortality. Unfortunately, our abdominal cocoon case was together with intestinal perforation caused by trauma and we obligated to intestinal resection and anastomosis.

Abdominal cocoon, or idiopathic sclerosing encapsulating peritonitis, is a rare condition of unknown cause characterized by total or partial encasement of the small bowel by a fibrocollagenous cocoon-like sac. The preoperative diagnosis of abdominal cocoon is usually difficult. An abdominal cocoon case who was operated due to trauma may be difficult to diagnose and treat in surgical emergency units. Therefore, a better awareness of this entity may facilitate diagnosis and treatment preoperatively.

## Competing interests

The authors declare that they have no competing interests.

## References

1. Foo KT, Ng KC, Rauff A, Foong WC, Sinniah R. Unusual small intestinal obstruction in adolescent girls: the abdominal cocoon. *Br J Surg* 1978;65:427-30.
2. Cleffken B, Sie G, Riedel R, Heineman E. Idiopathic sclerosing encapsulating peritonitis in a young female: diagnosis of abdominal cocoon. *J Pediatr Surg* 2008; 43:27-30.
3. Basu A, Sukumar R, Sistla SC, Jagdish S. "Idiopathic" abdominal cocoon. *Surgery* 2007;141:277-278.
4. Rokade ML, Ruparel M, Agrawal JB. Abdominal cocoon. *J Clin Ultrasound* 2007; 35:204-206.
5. Maguire D, Srinivasan P, O'Grady J, Rela M, Heaton ND. Sclerosing encapsulating peritonitis after orthotopic liver transplantation. *Am J Surg* 2001;182:151-154.
6. Rajagopal AS, Rajagopal R. Conundrum of the cocoon: report of a case and review of the literature. *Dis Colon Rectum* 2003;46:1141-1143.
7. Burstein M, Galun E, Ben-Chetrit E. Idiopathic sclerosing peritonitis in a man. *J Clin Gastroenterol* 1990;12:698-701.
8. Masuda C, Fujii Y, Kamiya T. Idiopathic sclerosing peritonitis in a man. *Intern Med* 1993;32:552-555.
9. Xu P, Chen LH, Li YM. Idiopathic sclerosing encapsulating peritonitis (or abdominal cocoon): a report of 5 cases. *World J Gastroenterol* 2007;13:3649-3651.
10. Aftentopoulos IE, Passadakis P, Oreopoulos DG, Bargman J. Sclerosing peritonitis in continuous ambulatory peritoneal dialysis patients: one center's experience and review of the literature. *Adv Ren Replace Ther* 1998;5:157-67.
11. Mann RD. An instructive example of a long-latency adverse drug reaction sclerosing peritonitis due to practolol. *Pharmacoevidenciol Drug Saf* 2007;16:1211-6.
12. Wei B, Wei HB, Guo WP, Zheng ZH, Huang Y, Hu BG, et al. Diagnosis and treatment of abdominal cocoon: a report of 24 cases. *Am J Surg* 2009;198:348-53.
13. Yeniyay L, Karaca CA, Çalışkan C, Fırat O, Ersin SM, Akgün E. Abdominal cocoon syndrome as a rare cause of mechanical bowel obstruction: report of two cases. *Ulus Travma Acil Cerrahi Derg*. 2011;17(6):557-60.
14. Jenny N Tannoury, Bassam N Abboud. Idiopathic sclerosing encapsulating peritonitis: Abdominal cocoon. *World J Gastroenterol* 2012 May 7;18(17):1999-2004.

## How to cite this article:

Oymacı E, Cartı EB, Uçar AD, Coşkun A, Yıldırım M, Erkan N. Abdominal Cocoon: A Rare and Difficult Togetherness in Trauma Patient. *J Clin Anal Med* 2016;7(4): 545-7.